

Reconstruction of a new pulmonary artery in arterial switch operation

Bai-Ping Sun, Shu Fang, Ze-Wei Zhang, Fang-Xia Chen, Jian-Hua Li, Ru Lin, Qiang Shu, Jian-Gen Yu

Hangzhou, China

Background: This study was undertaken to evaluate the new method for the reconstruction of the pulmonary artery in arterial switch operation (ASO).

Methods: A total of 108 consecutive infants with congenital heart disease were treated with ASO in our department between January 2004 and June 2012. The new pulmonary arterial root was reconstructed with a fresh autologous pericardium which was clipped pants-like with continuous mattress suture of 6-0 Prolene thread. Patients were reexamined consecutively at 3 and 6 months and 1, 2 and 6 years after discharge. The pulmonary arterial blood velocity was measured by continuous Doppler during systole. The pulmonary flow of healthy children of same age was also measured in the control group. Simplified Bernoulli formula was used to calculate the pressure gradient via the pulmonary artery for determining whether there was pulmonary stenosis.

Results: In this series, 96 infants survived after the surgery and 88 were followed up with a mean period of (22±4) months. No pulmonary stenosis was detected with the simplified Bernoulli formula.

Conclusion: No pulmonary stenosis was detected with the simplified Bernoulli formula.

World J Pediatr 2015;11(2):177-180

Key words: arterial switch operation; fresh autologous pericardium; pulmonary arterial reconstruction

Introduction

Arterial switch operation (ASO) has become the operative procedure of choice for infants born with transposition of the great arteries (dTGA) and certain forms of double outlet right ventricle (DORV) with subpulmonary ventricular septal defect (VSD). Over the past three decades, the results of ASO have progressively improved. However, it is reported that pulmonary artery stenosis is still the most commonly encountered complication after ASO.^[1-5] Pulmonary artery stenosis may occur in various ways. This study aimed to evaluate the new method for pulmonary artery reconstruction in arterial switch operation in a single center.

Methods

Patients

There were 108 consecutive infantal patients (95 were males and 13 females) who had undergone ASO for dTGA or DORV with subpulmonary VSD (Taussing-Bing heart) between January 2004 and June 2012. In this series, 96 patients had dTGA and 12 had DORV with subpulmonary VSD. Their mean age and mean body weight at the time of ASO were 18±21 days and 3.8±1.0 kg, respectively.

Operative techniques

Repair was performed with cardiopulmonary bypass (CPB) under moderate hypothermia (rectal temperature 26°C-30°C). Standard median sternotomy was performed. The pericardium was incised from the right side and lifted to the sternum, while the left portion was reserved for further use. The ductus arteriosus was ligated and severed at the beginning of CPB. The pulmonary arteries were dissected down to the pulmonary hilum to gain a sufficient length. The aorta

Author Affiliations: Department of Thoracic and Cardiovascular Surgery, Children's Hospital of Zhejiang University School of Medicine, 57 Zhugan Xiang, Hangzhou 310003, China (Sun BP, Fang S, Zhang ZW, Chen FX, Li JH, Lin R, Shu Q, Yu JG)

Corresponding Author: Jian-Gen Yu, Department of Thoracic and Cardiovascular Surgery, Children's Hospital, Zhejiang University School of Medicine, 57 Zhugan Xiang, Hangzhou 310003, China (Tel: 86-0571-87061007 ext 60611; Fax: 86-0571-87033296; Email: yujiangen@hotmail.com)

doi: 10.1007/s12519-014-0473-1

©Children's Hospital, Zhejiang University School of Medicine, China and Springer-Verlag Berlin Heidelberg 2014. All rights reserved.

and main pulmonary artery were transected above the semilunar valves. The coronary arteries were translocated to the native pulmonary root. The Lecompte manoeuvre was performed. The neo-aortic root was anastomosed to the ascending aorta.^[1,4,5,6] The new pulmonary root was reconstructed with previously reserved left side fresh autologous pericardium, which was clipped like pantaloons and with continuous mattress suture of 6-0 Prolene thread (Fig.). After the reconstruction of the pulmonary root, the proximal and distal pulmonary anastomosis was fashioned using continuous suture of 6-0 Prolene. Atrial septal defects or ventricular septal defects were closed. The aortic cross clamp was released after deaeration. CPB was discontinued once rewarming and resumption of heart function were adequate. Blood was ultrafiltered with a filter set in the cardiopulmonary circuit during CPB to reduce the amount of interstitial edema. The sternum was usually left open for two to three days because of hemodynamic instability between January 2004 and December 2010,^[7] and routine primary chest closure from January 2011.

Echocardiographic measurements

Postoperative pulmonary flow velocity was measured with echocardiography by a single observer blinded to outcome. A continuous Doppler was used to measure the

pulmonary flow velocity during systole. The pulmonary artery pressure gradient was calculated with the simplified Bernoulli formula. Pulmonary artery pressure gradient >30 mmHg indicates pulmonary stenosis at peak systole.

Statistical analysis

Statistical analysis was performed using SPSS 11.0 software. All descriptive data were expressed as mean±SD. Student's *t* test was used to compare values in the present study with those of normal children matched for age and weight taken from the published normal values.^[8] A $P \leq 0.05$ was considered statistically significant.

Results

Of the 108 infants, 96 survivors were included in the present study. A total of 220 echocardiogram examinations were performed in 88 (91.7%) of the 96 survivors at the postoperative follow-up visits. Follow-up time ranged from 3 to 72 months, with a mean of 22±4 months. The number of patients who were tested with echocardiography during 3 months<age≤5 months, 5 months<age≤9 months, 9 months<age≤1.5 year, 1.5 year<age≤4 year, and 4 year<age were 88, 67, 45, 20, and 10, respectively. The follow-up outcomes of the patients are shown in Table. The pulmonary flow

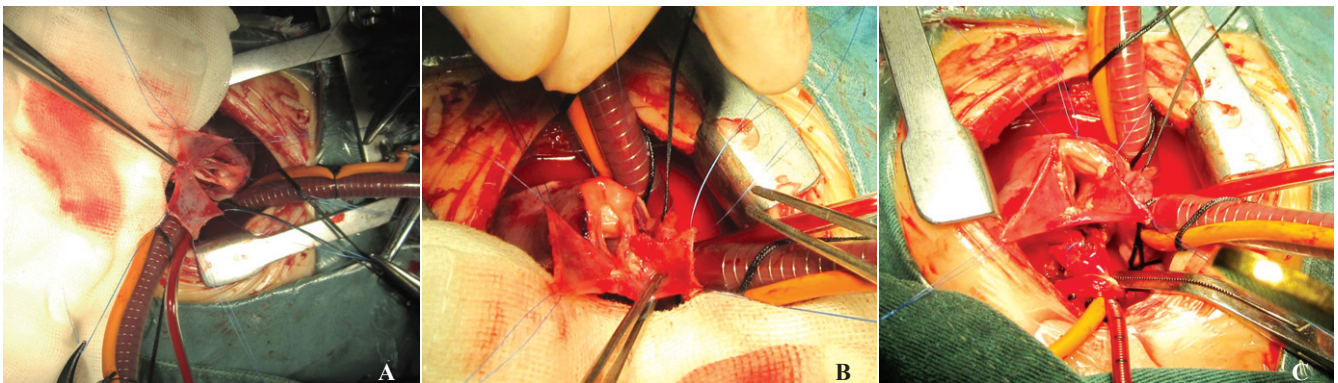


Fig. A: Fresh autologous pericardium was clipped like pantaloons and traction four corners for flat; **B:** Patch straddling sewn at the commissure of the sinus wall; **C:** The new pulmonary root was reconstructed.

Table. The follow-up outcome of patients

Variables	Age at follow-up				
	3 mon<age≤5 mon	5 mon<age≤9 mon	9 mon<age≤1.5 y	1.5 y<age≤4 y	>4y
<i>n</i>	88	67	45	20	10
0.7<V≤1.3	79	52	33	15	6
1.3<V≤2.16	9	15	12	5	4
MPFV(m/s)	1.18±0.25	1.27±0.46	1.44±0.43	1.30±0.32	1.54±0.38
TPAP (mmHg)	4.80±3.40	6.50±3.60	9.20±3.30	11.30±4.20	12.80±5.40

MPFV: mean pulmonary flow velocity; TPAP: trans-pulmonary arterial pressure; V: velocity of flow.

velocity was 0.70-2.16 m/s. The mean trans-pulmonary gradient increased with age, but no pulmonary stenosis was found using the simplified Bernoulli formula so far. Three patients showed insufficiency of mild pulmonary arterial valve but no patient had moderate or severe insufficiency.

Discussion

Pulmonary artery stenosis is widely recognized as the most frequent complication after ASO, and the reported incidence ranges considerably from 3% to 30%.^[1-5] Different mechanisms of pulmonary artery stenosis have been reported.

An important cause might be the employed technique for the reconstruction of the pulmonary artery. The tension at the anastomotic site has been recognized as a possible adjunctive factor for inadequate somatic growth at the suture line. Such a tension is higher when a direct anastomosis is made between the distal and proximal ends of the pulmonary artery.^[2] Moreover, the size discrepancy between the aorta and the pulmonary artery before operation makes the reconstruction of the pulmonary artery more difficult and, it may cause troubles and do harm to the growth of the pulmonary artery.^[1,8] Other possible mechanisms may be the presence of ductal tissue which may cause the so called "coarctation" of the left pulmonary artery and the "bowstring" of the left pulmonary artery over the aorta after the Lecompte manoeuvre, resulting in significant flow asymmetry especially when the distal pulmonary artery is not extensively mobilized.^[3,4,9]

In our patients, the ductus arteriosus was severed at the beginning of CPB to avoid ductal tissue-caused "coarctation" of the pulmonary artery. We dissected the pulmonary arteries down to the pulmonary hilum to gain a sufficient and tension-free length after the Lecompte manoeuvre.

We reconstructed the pulmonary arterial root using a pantloon-like fresh autologous pericardium with continuous suture of 6-0 Prolene thread to avoid pulmonary artery stenosis. The "pantloon patch" has two characteristic advantages. First, it helps to maintain the support structure of the pulmonary artery. And the middle cut section of the patch riding on the junction of the sinus wall with cross-stitch acts as a pedicle that supplies blood and nutrition and promotes pulmonary artery endothelial cell growth and spread to patch formation. The fresh autologous pericardium patch was preferred in promoting pulmonary artery endothelial cell growth and spread to patch treated with 0.6% glutaraldehyde in the long run. Adachi

et al^[10] found that the autologous pericardium patch with a pedicle has the growth. Second, the "pantloon patch" technique provides an additional length for a complete pulmonary circumferential anastomosis and tissue quantity to the proximal neopulmonary root, and reduces the tension at the anastomotic site. We also used continuous screwy suture of 6-0 Prolene thread between the distal and proximal ends of the pulmonary artery. The suture is actually spiral, and like a spring it stretches out of straight as the vessels enlarge under blood pressure, whether it is a fracture of fine 6/0 and 7/0 polypropylene thread that permits the growth.^[11,12]

The blood speed at pulmonary artery anastomosis was 0.70-2.16 m/s. At 22±4 months after ASO, the mean pulmonary flow velocity was 1.31±0.40 m/s, which implied the trans-pulmonary gradient was calculated 12.8±5.4 mmHg using the simplified Bernoulli formula. The mean trans-pulmonary gradient increased significantly as in our series. The data of Yamaguchi et al^[13] suggested that supravalvular obstruction after ASO is progressive with age. The fact that none of our patients had pulmonary artery stenosis so far was encouraging. However, as the follow-up time was relatively short, long-term follow up is needed for understanding more on pulmonary arteries after ASO.

Funding: This project was supported by grants from the Science and Technology Commission of Zhejiang, China (2010R50045), Ministry of Education Doctoral Station Foundation (20120101110049), and the National Science and Technology Support Program (2012BAI04B05).

Ethical approval: Not needed.

Competing interest: None declared.

Contributors: Sun BP wrote the first draft. Chen FX reviewed the manuscript. Yu JG and Zhang ZW proposed the study. All authors contributed to the design and interpretation of the study.

References

- 1 Griselli M, McGuirk SP, Ko CS, Clarke AJ, Barron DJ, Brawn WJ. Arterial switch operation in patients with Taussig-Bing anomaly-influence of staged repair and coronary anatomy on outcome. *Eur J Cardiothorac Surg* 2007;31:229-235.
- 2 Prifti E, Crucean A, Bonacchi M, Bernabei M, Murzi B, Luisi SV, et al. Early and long term outcome of the arterial switch operation for transposition of the great arteries: predictors and functional evaluation. *Eur J Cardiothorac Surg* 2002;22:864-873.
- 3 Prandstetter C, Hofer A, Lechner E, Mair R, Sames-Dolzer E, Tulzer G. Early and mid-term outcome of the arterial switch operation in 114 consecutive patients, A single centre experience. *Clin Res Cardiol* 2007;96:723-729.
- 4 Prêtre R, Tamisier D, Bonhoeffer P, Mauriat P, Pouard P, Sidi D, et al. Results of the arterial switch operation in neonates with transposed great arteries. *Lancet* 2001;357:1826-1830.

- 5 Wetter J, Belli E, Sinzobahamvya N, Blaschzok HC, Brecher AM, Urban AE. Transposition of the great arteries associated with ventricular septal defect: surgical results and long-term outcome. *Eur J Cardiothorac Surg* 2001;20:816-823.
- 6 Losay J, Touchot A, Capderou A, Piot JD, Belli E, Planché C, et al. Aortic valve regurgitation after arterial switch operation for transposition of the great arteries: incidence, risk factors, and outcome. *J Am Coll Cardiol* 2006;47:2057-2062.
- 7 Zhu LX, Tan LH, He XJ, Zhang CY, Yu YP, Zhang ZW. Postoperative complications and their management after arterial switch operation in infants with transposition of the great arteries. *World J Pediatr* 2007;3:300-304.
- 8 Moller JH, Neal WA. Fetal, neonatal, and infant cardiac disease. USA: Bermedica Production, 1990: 275.
- 9 Blume ED, Altmann K, Mayer JE, Colan SD, Gauvreau K, Geva T. Evolution of risk factors influencing early mortality of the arterial switch operation. *J Am Coll Cardiol* 1999;33:1702-1709.
- 10 Adachi I, Yagihara T, Ishibashi-Ueda H, Kitamura S. Immunohistological findings for an extracardiac conduit in Fontan pathway constructed with pedicled autologous pericardium. *Eur J Cardiothorac Surg* 2006;29:1059-1060.
- 11 Jonas RA. Comprehensive surgical management of congenital heart disease. London: Butler and Tanner Ltd, 2004: 20-21.
- 12 Schlichter AJ, Kreutzer C, Mayorquim RC, Simon JL, Román MI, Vazquez H, et al. Five to fifteen year follow-up of fresh autologous pericardial valved conduits. *J Thorac Cardiovasc Surg* 2000;119:869-879.
- 13 Yamaguchi M, Hosokawa Y, Imai Y, Kurosawa H, Yasui H, Yagihara T, et al. Early and mid-term results of the arterial switch operation for transposition of the great arteries in Japan. *J Thorac Cardiovasc Surg* 1990;100:261-269.

*Received August 28, 2013
Accepted after revision July 8, 2014*